

Sinonasal Teratocarcinoma: Management and Literature review

TAHIR RASHID, SALMAN BAIG, IMRAN SAEED*, ZAYED MAHASIN**

ABSTRACT

Teratocarcinomas of sinonasal tract are very rare, histologically distinctive and highly malignant tumours containing both epithelial and mesenchymal elements. Around 66 cases have been reported in the world literature. Sinonasal teratocarcinoma is predominantly found in males, most commonly affecting the nasal cavities and paranasal sinuses. The tumour's aggressive and infiltrative behaviour leads to local recurrences and eventual treatment failure. The widely accepted treatment of choice for these tumours is surgery followed by radiotherapy. Due to the aggressive nature of the tumour, it has a tendency to recur and therefore a close follow-up following radical surgery and adjuvant radiotherapy is recommended. Chemotherapy has been used in recurrent and metastatic disease. However there is no convincing evidence that it increases the overall cure rate and survival. We report a case of a 32 years old male who was referred to our hospital with a diagnosis of sinonasal teratocarcinoma of the left ethmoid following functional endoscopic sinus surgery for nasal polyposis. We carried out an anterior craniofacial resection of the tumour followed by radiotherapy.

Key words: Teratocarcinoma, sinonasal

INTRODUCTION

Sinonasal teratocarcinoma is a rare and unique tumour consisting of epithelial and one or more connective tissue elements.¹ Many names have been used in the past for this entity such as malignant teratoma, carcinosarcoma, blastoma, mixed mesodermal tumour². Heffner and Hyams in 1984 introduced the name teratocarcinoma, which explains the complex histological pattern of teratomas and carcinosarcomas^{3,4}. Around 66 cases have been reported in the literature. Teratocarcinoma almost exclusively arises in the sinonasal tract⁵. Only a few teratocarcinomas outside the sinonasal tract have been described and these are found in nasopharynx and pharynx^{3,5,6}. It is predominantly found in males and most commonly presents with nasal obstruction and epistaxis⁷. Headache, dizziness, focal neurological signs and visual disturbances occur when tumour extends to adjacent areas such as the cranial cavity and orbit.^{1,8} Due to its aggressive nature over one-third of sinonasal teratocarcinomas tend to recur leading to treatment failure with a mean survival time of 1.9 years^{5,9}. Distant metastases are very rare.

Three and five year survival rate is about 30% and 20% respectively.³ Surgery, radiotherapy and chemotherapy have been used for treatment but surgery followed by radiotherapy is the preferred treatment of choice.

CASE REPORT

A 32 years old male patient presented with a five month history of left sided intermittent epistaxis and nasal obstruction at the referring hospital. Functional Endoscopic Sinus Surgery was performed. Histopathology came back as teratocarcinoma. It was at this point that the patient was referred to our hospital for further management. Patient was asymptomatic on presentation. Clinical examination by an endoscope revealed a small mass in the superior part of the left nasal cavity. Computerized Tomography (CT) Scan with contrast of the paranasal sinuses and brain revealed a 3.5 cm. by 1.5 cm mass located in the left anterior ethmoid cells with moderate but patchy contrast enhancement. Although the mass was involving the cribriform plate, there was no intracranial involvement. There was no intra orbital extension (Fig 1). A Positron Emission Tomography (PET) scan using 18-fluorodeoxyglucose confirmed a hyper metabolic mass in the left nasal cavity (Fig 2). The histopathology was reviewed at our hospital and the diagnosis of sinonasal teratocarcinoma (SN TCS) was confirmed. Fine needle aspiration of an incidental thyroid nodule, noted on the CT scan, was

*Assistant Professor Paediatric ENT, The Children's Hospital, Lahore

**Department of Otolaryngology/Head and Neck Surgery and Communication Sciences, King Faisal Specialist Hospital and Research Centre, Riyadh. Kingdom of Saudi Arabia.

Correspondence to Dr. Tahir Rashid, Assistant Professor, F. J. Medical College, Lahore 107 Q, Model Town Extension, tahir1964@hotmail.com

reported as a colloid nodule with no evidence of any metastatic disease. Furthermore, this nodule was not having a significant uptake on PET scan. The case was reviewed at the joint departmental tumour board meeting and decision was made to proceed with radical surgical resection followed by radiotherapy.

After obtaining an informed consent, the surgery was performed in conjunction with the neurosurgical team. Anterior craniofacial resection was carried out using a bicoronal frontal craniotomy approach along with lateral rhinotomy. Tumour was resected en bloc including the cribriform plate, upper part of the perpendicular plate of the ethmoid and cartilaginous septum and the whole of the left lateral nasal wall, to ensure complete excision. The resulting defect in the anterior skull base was repaired by a dural graft in order to separate the cranial and the nasal cavities. To ensure clear margins, intra operative frozen sections were sent, and were reported as negative. Patient made an uneventful post operative recovery and was discharged a week after the procedure. Post operative CT scan was done prior to discharge and showed no residual tumour (Fig 3). Histopathology of the specimen was reported as sinonasal teratocarcinoma without bone or cartilage involvement. Post operatively, radiotherapy treatment was administered. The patient is scheduled for monthly follow ups to detect any early recurrences of the tumour.

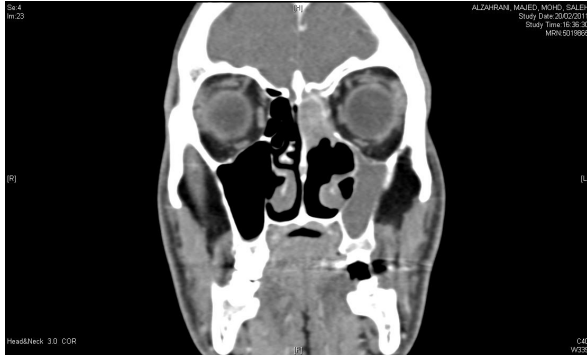


Fig 1. Tumour in the left ethmoid sinus involving the cribriform plate and upper part of nasal septum.

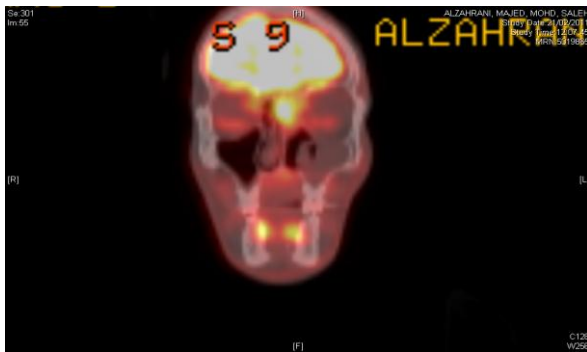


Fig 2. Left ethmoid tumour showing intense uptake on pet scan.

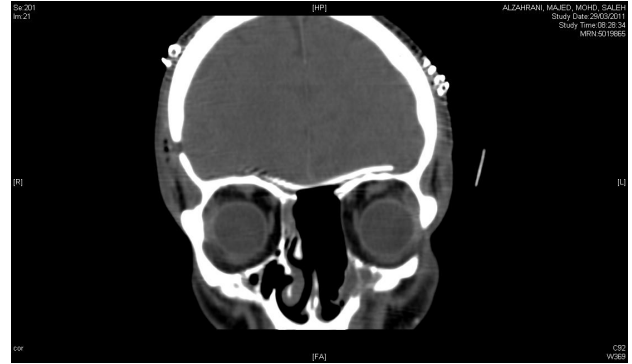


Fig 3. Post operative CT scan shows defect in the ethmoid cribriform plate and upper part of septum with duraplast in place and few clips in the scalp.

DISCUSSION

Sinonasal teratocarcinoma is an extremely rare aggressive malignant neoplasm with polymorphous features that combine high grade carcinosarcoma and teratoma.⁴ The tumour manifests both benign and malignant components.¹⁰ Many names have been attributed to this tumour in the past but Heffner & Hyam in 1984 proposed the designation of the unique term teratocarcinoma through their review of 20 cases, which is widely accepted since then².

Sinonasal teratocarcinoma predominantly occur in males (M:F 8:1). Ninety percent of the patients at presentation were 35 years and above with a mean age of 61 years. However a case as young as 27 days has also been reported.^{4,6,11} Sinonasal teratocarcinoma most commonly arises from nose, ethmoid and maxillary sinuses, while a single case of sphenoid sinus sinonasal teratocarcinoma has been reported¹². Our present case of a young male patient, 32 years of age, with ethmoid involvement conforms to previous reviews. Nasal obstruction, discharge and episodes of epistaxis are the common presenting features, while headache, dizziness and focal neurological deficits due to tumour extension can present in isolated cases^{1,8}.

Histologically sinonasal teratocarcinomas are characterized by various combinations of benign and malignant elements of bone, muscle and cartilage along with glandular, neuroendocrine, neuroepithelial and epidermoid tissues⁵. Detailed and thorough examination of histological specimen is essential for diagnosis¹³ along with CT scan and MRI. Histologically, differential diagnosis include carcinomas, sarcomas, neuroendocrine tumours, lymphoma and melanoma. Lymphoma and melanomas are excluded by negativity of tumour markers⁹.

Review of the current literature shows that the general consensus treatment of choice of sinonasal teratocarcinoma is radical and complete resection followed by postoperative adjuvant radiotherapy^{3,14,15} and we followed this advice for our patient. Chemotherapy has been used for few extensive and recurrent cases. Due to the rare nature of the tumour, it is difficult to collect reasonable evidence of an improved cure rate following chemotherapy. Previous studies clearly demonstrated that patients who did not receive postoperative radiotherapy had a higher rate of recurrence when compared to those who had radiotherapy.^{16,17} Sinonasal teratocarcinomas are aggressive tumours and consequently more than half of the patients die within three years. (Heffner/Hyams). A high recurrence rate of approximately 37% further confirms their aggressive nature. Distant metastases are rare as the tumour is locally very aggressive but lung metastases have been reported⁷. Three and five years survival rate is about 30% and 20% respectively³.

In conclusion sinonasal teratocarcinoma is a rare but extremely malignant tumour with high incidence of recurrence and a poor survival rate. In view of these facts and the general consensus of the currently published literature, we adopted an aggressive approach of wide and adequate excision by means of an anterior craniofacial resection followed by adjuvant radiation treatment. In order to detect any potential early recurrences a monthly follow-up with a thorough examination of the nasal cavity is essential.

REFERENCES

1. Takasaki K, Sakihama N, Takasaki H. A case with sinonasal teratocarcinoma in the nasal cavity and ethmoid sinus. *Eur Arch Otorhinolaryngol* 2006;263:586-91.
2. Salem F, Rosenblum MK, Jhanwar SC et al. Teratocarcinoma of the nasal cavity and paranasal sinuses: report of 3 cases with assessment for chromosome 12p status. *Human Pathology* 2008;39:605-09.
3. Heffner DK, Hyams VJ. Teratocarcinoma (malignant teratoma?) of the nasal cavity and paranasal sinuses. A clinicopathologic study of 20 cases. *Cancer* 1984;53:2140-54.
4. Sharma HS, Abdullah JM, Othman NH et al. Teratocarcinoma of the nasal cavity and ethmoid. *J Laryngol Otol* 1998;112:682-6.
5. Carrizo F, Pineda DK, Neto AG et al. Pharyngeal teratocarcinoma: review of the literature and report of two cases. *Ann Diagn Pathol* 2006;10:339-42.
6. Rotenberg B, El-Hakim H, Lodha A et al. Nasopharyngeal teratocarcinoma. *Int J pediatr Otorhinolaryngol* 2002;62:159-64.
7. Su YY, Friedman M, Huang CC et al. Sinonasal teratocarcinoma. *Am J Otolaryngol- Head and Neck Medicine and Surgery* 2010;31:300-03.
8. Chao KK, Eng TY, Barnes J et al. Sinonasal teratocarcinoma. *Am j Clin Oncol* 2004;27:29-32.
9. Wei S, Carroll W, Lazenby A et al. Sinonasal teratocarcinoma: report of a case with review of the literature and treatment outcome. *Ann Diagn Pathol* 2008;12:415-25.
10. Thomas J, Adegboyega P, Iloabachie K et al. Sinonasal teratocarcinoma with yolk sac elements: a neoplasm of somatic or germ cell origin? *Ann Diagn Pathol* 2011;15:135-39.
11. Crazzolara R, Puelacher W, Ninkovic M et al. Teratocarcinoma of the oral cavity. *Pediatr Blood Cancer* 2004;43:687-91.
12. Shemen L, Galantich P, Murali R. Malignant teratocarcinoma of the sphenoid sinus. *Otolaryngol Head Neck Surg* 1995;112(3):496-500.
13. Oka K, Kanayama R, Fukunaga M et al. Nasal teratocarcinoma- A case report. *Pathol Research and Practice* 2007;203:549-53.
14. Dicke TE, Gates GA. Malignant teratoma of the paranasal sinuses. Report of a case. *Arch Otolaryngol* 1970;91:391-94.
15. Prasad KC, Pai RR, Padmanaghan K et al. Teratocarcinoma of the nose, paranasal sinuses and nasopharynx. *J Laryngol Otol* 2003;117:321-24.
16. Devgan BK, Devgan M, Gross CW. Teratocarcinoma of the ethmoid sinus: review of literature plus a new case report. *Otolaryngology* 1978;86:689-95.
17. Fernandez PL, Cardesa A, Alos L et al. Sinonasal teratocarcinoma: an unusual neoplasm. *Pathol Res Pract* 1995;191:166-71.